



# A CASE OF ABNORMAL HAIR, IMMUNODEFICIENCY AND HLH

---

Julia Damásio de Castro Coutinho

Hospital das Clínicas

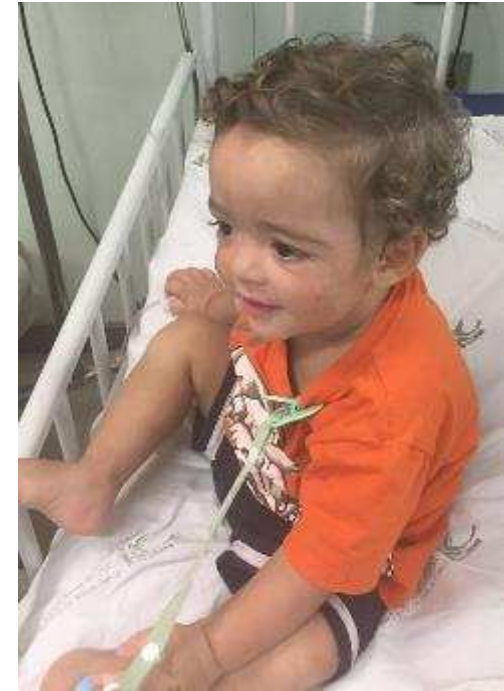
Federal University of Minas Gerais

Belo Horizonte – Minas Gerais - Brasil

- 18 months male infant
- No family history of early deaths
- Parents are first degree cousins

- **Clinical features:**

- Hepatosplenomegaly
- Fever
- Multiple episodes of pneumonia
- Normal height and weight for his age
- Normal development



Noticed at 4 months of age

## Laboratory workout

- Neutropenia
  - Anemia
- ## Images

- Hepatosplenomegaly on abdominal ultrasound

## Hair analysis



Fig 3: control    Fig 4: patient

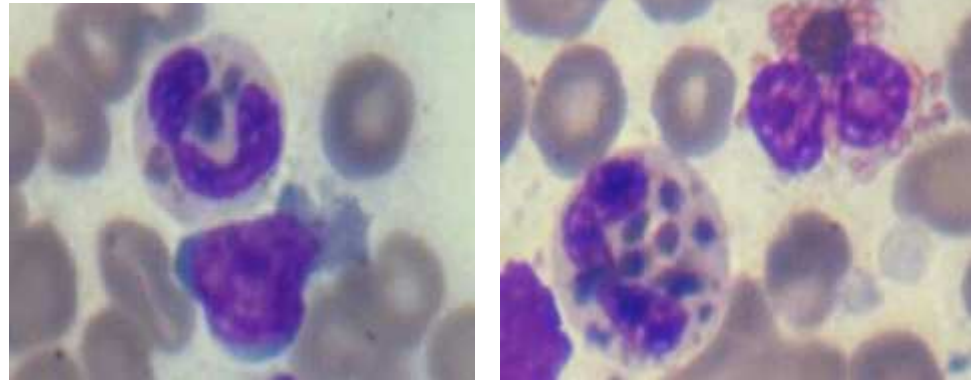


Fig1and 2: Images from peripheral blood cells

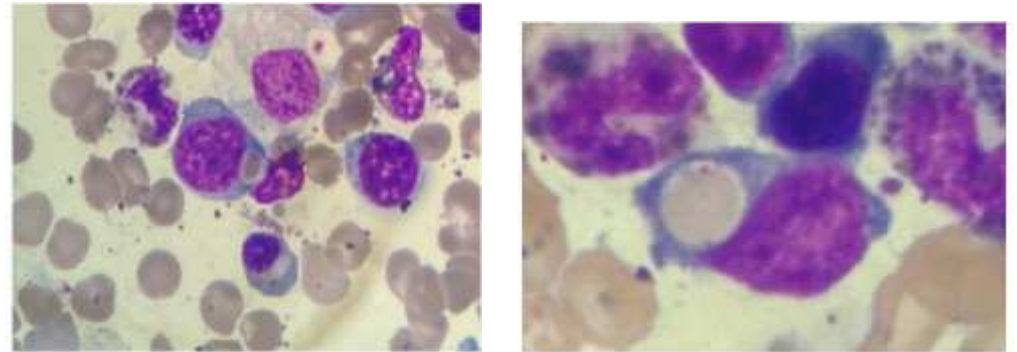



Fig 5 and 6: Images from bone marrow analysis

Fig 3 and 4 gently provided by Dr Rosenzweig



Fever + Cytopenia + Hepatosplenomegaly + images of Hemophagocytosis on bone marrow



**Hemophagocytic Lymphohistiocytosis (HLH) - accelerated phase**



HLH 2004 Protocol treatment  
(Etoposide, dexamethasone, cyclosporine A, intratecal injection with methotrexate and prednisolone)

- Developed BCGitis after HLH protocol was initiated
- Treated with RIE
- He is waiting for a haploidentical bone marrow transplant using his mother as the donor.

What is the diagnoses????

**Chediak Higashi**

THANK YOU!

